

# Effect of Lichen Sclerosis on Success of Urethroplasty



Michael A. Granieri, MD, Andrew C. Peterson, MD\*,  
Ramiro J. Madden-Fuentes, MD

## KEYWORDS

- Lichen sclerosis • Urethroplasty • Urethral stricture • Balanitis xerotica obliterans
- Perineal urethrostomy

## KEY POINTS

- Lichen sclerosis is a chronic inflammatory skin disease with a variable presentation commonly affecting the anogenital area in both men and women.
- Management of urogenital lichen sclerosis is predicated on the extent of disease.
- Most patients can be treated with conservative therapies consisting of minimally invasive surgical techniques and potent topical steroids.
- Surgical intervention may be indicated when the disease process is extensive or recalcitrant to conservative therapy.
- Perineal urethrostomy is an attractive option with high patient satisfaction for extensive urethral lichen sclerosis in patients who are unwilling or unfit for 2-stage repair.

## INTRODUCTION

Lichen sclerosis (LS), previously termed balanitis xerotica obliterans, is a chronic inflammatory skin disease commonly affecting the anogenital area in both men and women. In 1976, the International Society for the Study of Vulvovaginal Disease concluded that the terminology LS should be adopted for men and women.<sup>1</sup> In men, it commonly manifests in excess of simple balanitis, hence the accepted change in terminology. The presentation of LS in both men and women is variable and ranges from a focal disease process to an extensive degree of involvement presenting in childhood or adulthood. It may extend beyond the glans penis and affect the penile shaft skin, urethral meatus, and urethra.<sup>2,3</sup> Consequently, the diverse presentation means diverse treatment

is necessary with variable success rates. A higher predilection of LS in women compared with men is well established. Urethral involvement of LS is largely seen in men, however.<sup>4</sup> The extent of urethral disease may be limited to the urethral meatus or progress to panurethral involvement.

In this article, the authors describe the presentation, pathogenesis, epidemiology, and their current management algorithm for male patients with LS.

## PRESENTATION

Genital involvement with LS may present with local pruritus, dysuria, phimosis, paraphimosis, fissures, whitish skin, and bothersome lower urinary tract symptoms (LUTS) when the urethra is involved (**Fig. 1**). Riddell and colleagues<sup>5</sup> reported

---

Disclosure Statement: There are no conflicts of interest. No sources of external funding to be reported. Division of Urology, Department of Surgery, Duke University Medical Center, DUMC 3146, Durham, NC 27710, USA

\* Corresponding author.

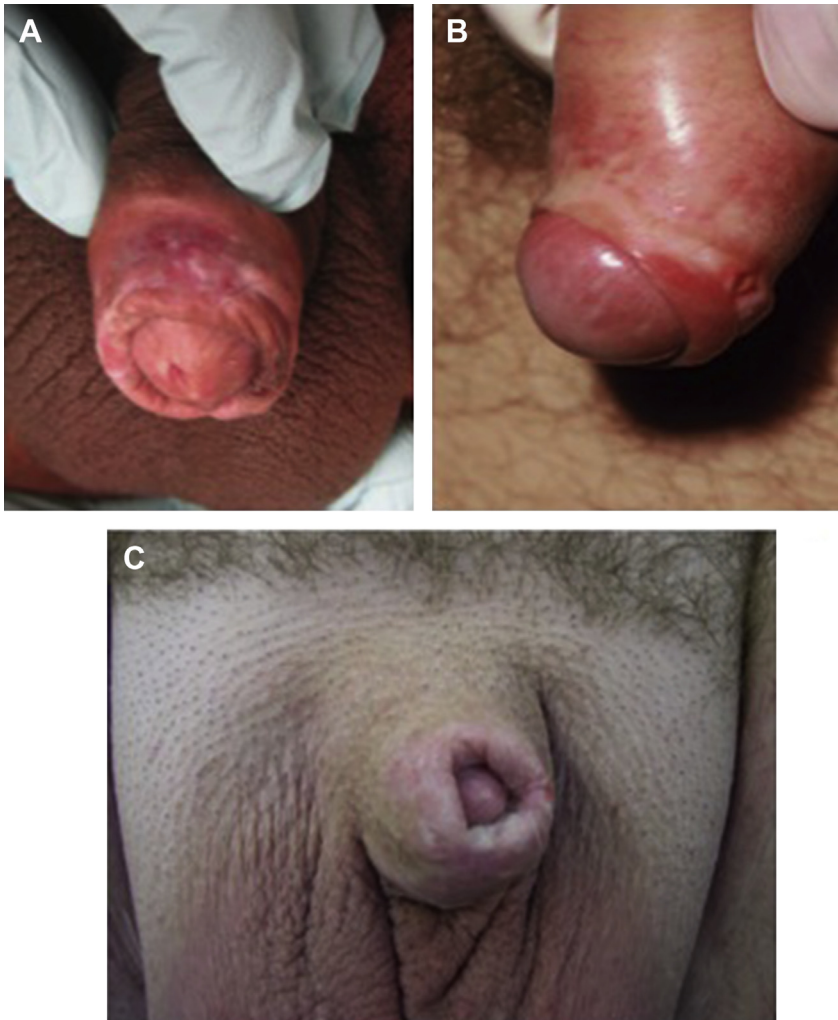
E-mail address: [Drew.Peterson@duke.edu](mailto:Drew.Peterson@duke.edu)

Urol Clin N Am 44 (2017) 77–86

<http://dx.doi.org/10.1016/j.ucl.2016.08.004>

0094-0143/17/© 2016 Elsevier Inc. All rights reserved.

Downloaded from ClinicalKey.com at President and Fellows of Harvard College on behalf of Harvard University January 11, 2017.  
For personal use only. No other uses without permission. Copyright ©2017. Elsevier Inc. All rights reserved.



**Fig. 1.** Variable presentation of LS. (A) Whitish discoloration, with foreskin fissuring and glans irritation. (B) Phimosis, skin thinning, glans and preputial irritation. (C) Buried penis, penile entrapment, dense scarring.

common symptoms in patients diagnosed with LS. Tight foreskin was noted in 25.8%, pruritus in 18%, painful erections in 13.6%, and cracking and bleeding in 9.1%. Up to 19.7% of patients reported difficulty passing urine, which raises concern for either meatal or urethral involvement. Chronic inflammatory changes may be associated with genital ulceration and superimposed infections. Significant scarring and genital deformation may be noted as a consequence.

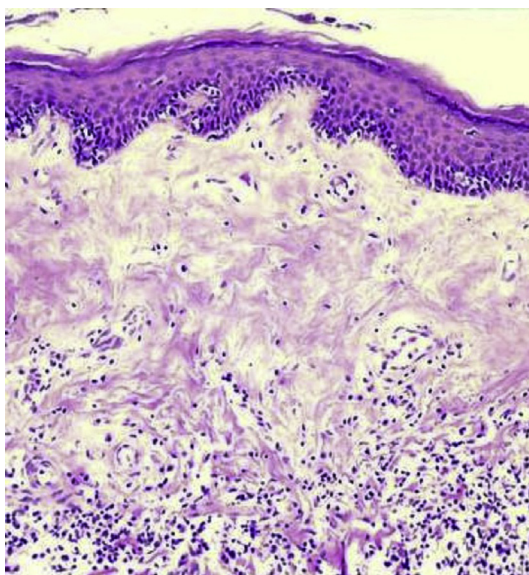
### **PATHOGENESIS**

LS is characterized microscopically by the presence of hyperkeratosis, thinning of the epidermis, loss of rete pegs, and collagen deposition in the dermis (Fig. 2). A histiocytic or lymphocytic infiltrate is also noted and has led to the theory of an

inflammatory cause.<sup>6,7</sup> A variety of precipitating factors, including autoimmune processes, infections, and trauma, have also been suggested to contribute to the development of LS.

### **Autoimmunity**

Immune-related dysregulation has been suggested as the cause of LS. Histopathologic findings of abnormal T-cell clones in the lymphocytic infiltrate of tissue affected by LS argue for autoimmune dysregulation as the underlying factor leading to pathogenesis.<sup>8</sup> Attempts at identification of a putative antigen suggest that extracellular matrix protein 1 (ECM1) may play a role. Initially, this was suggested by the overlapping dermatologic clinical and histologic findings between lipid proteinosis and LS. Lipid proteinosis is an



**Fig. 2.** Skin diseased by LS (hematoxylin-eosin, original magnification  $\times 100$ ). Loss of rete pegs, collagen deposition, lymphocytic infiltrate are all noted.

autosomal-recessive genetic disorder leading to loss of function of ECM1. Circulating antibodies to ECM1 have been noted in a higher proportion of patients with LS than controls.<sup>9</sup> Debate still remains whether these circulating antibodies are due to exposure of the site-specific antigens from another inciting event, or whether circulating antibodies are the cause of the genital skin changes.

In addition, other studies have also suggested a genetic susceptibility and autoimmune basis to LS. Bjekic and colleagues,<sup>10</sup> in a case control study of 73 patients with LS, noted an association between the presence of LS and prior genital injury, vitiligo, family history of alopecia areata, and thyroid gland disease. Azurdia and colleagues<sup>6</sup> compared a cohort of biopsy-proven LS patients with controls and found an increased frequency of class II HLA antigens DR11, DR12, and DQ7, suggesting an immunopathogenesis for this disease.

### **Infection**

An infectious pathogen has been suggested as a potential driving factor for LS based on histologic evaluation of skin biopsies. A few studies have linked spirochetes, *Borrelia burgdorferi*, and acid-fast bacilli to LS.<sup>11,12</sup> However, others have attempted to confirm these findings and have failed to demonstrate a correlation in specimens of LS.<sup>13,14</sup> At the current time, the authors think that the evidence does not support infection as the cause of LS.

### **Trauma**

The Koebner phenomenon is described as dermal lesions arising from trauma and has been suggested as a cause for LS.<sup>15</sup> Various reports suggest the development of LS after circumcision at suture lines as well as following sunburns and radiation therapy.<sup>4,16,17</sup> It remains unclear if these events herald the development of the immunopathogenesis resulting in LS in susceptible patients.

### **Degeneration to Malignancy**

Importantly, LS is a relapsing and progressive disease with reported degeneration to squamous cell carcinoma (SCC). However, a direct causation has not been reliably described. Most reports have identified LS changes in the background of SCC. No published prospective cohort of patients diagnosed with LS has been reported to then ascertain the incidence of subsequent SCC.

Depasquale and colleagues<sup>18</sup> reported 522 men surgically treated for LS and noted a 2.3% rate of associated SCC. In this cohort, the indication for surgery was SCC and LS was a secondary finding. Given that many of the patients were referred for surgical treatment of SCC, these data do not necessarily suggest LS as a precursor to SCC. There are other reports associating LS with SCC. Barbagli and colleagues<sup>19</sup> reported 130 men with surgically treated LS and noted an 8.4% rate of premalignant or malignant histopathological features on re-review of the pathologic specimens. Similarly, of 20 patients with confirmed penile carcinoma, Powell and colleagues<sup>20</sup> noted that 50% of those patients had SCC in a background of LS. Last, Velazquez and Cubilla<sup>21</sup> reported 68 patients with known SCC and found LS in 33% of the specimens. The authors have longitudinally followed a cohort of men with biopsy-proven LS. Of 68 patients with biopsy-proven LS followed for a mean of 36 months, there were no instances of development of SCC or premalignant lesions.<sup>22</sup> To the authors' knowledge, this is the only report to date that has longitudinally followed patients with biopsy-proven LS.

The current data are unclear regarding the role of LS in the subsequent development of SCC. Although the authors' experience has not demonstrated degeneration to malignancy, longer follow-up interval with a larger number of patients will provide further insight into this critical question.

### **EPIDEMIOLOGY**

The true prevalence of LS in men is likely underreported, because many affected individuals will have minimally symptomatic disease. In children

presenting with phimosis for circumcision, pathologic analysis has shown that LS may be present in up to 20% to 30% of patients.<sup>23–25</sup> An estimated 28% of men seen in an outpatient clinic diagnosed with LS by physical examination were asymptomatic.<sup>5</sup> In 1971, Wallace<sup>26</sup> reported an estimated prevalence of LS between 1 in 300 and 1 in 1000 in a cohort of men referred to a community-based dermatology clinic. The age of presentation has been reported highest in the third and fourth decade of life.<sup>27</sup> However, in a large cohort of Department of Defense beneficiaries, the age distribution was more than double in the fourth and fifth decade of life compared with the first 3 decades. The highest prevalence was seen in men greater than 61 years old.<sup>28</sup>

Management of urogenital LS is predicated on the extent of disease, and because of its variable presentation, this ranges from conservative therapy to surgical intervention. Depasquale and colleagues<sup>18</sup> reported 428 men with LS as the primary disease process. In this cohort, 70.1% of patients had LS involving only the foreskin and glans, 4.9% the urethral meatus, and 20% the urethra. In patients with disease limited to the foreskin or glans circumcision, topical therapies may be sufficient. However, in cases of severe glanular, meatal, or urethral involvement, more aggressive surgical therapies are necessary.

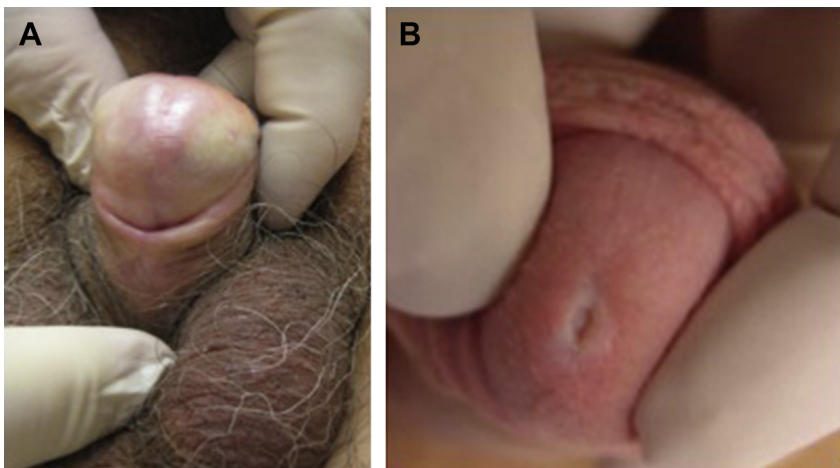
### EVALUATION FOR PENILE/URETHRAL DISEASE

Although the diagnosis of LS is often from history and physical examination (see [Fig. 1](#); [Fig. 3](#)), several skin disorders, such as scleroderma, penile intraepithelial neoplasia (previously known as erythroplasia of Queyrat and Bowen disease),

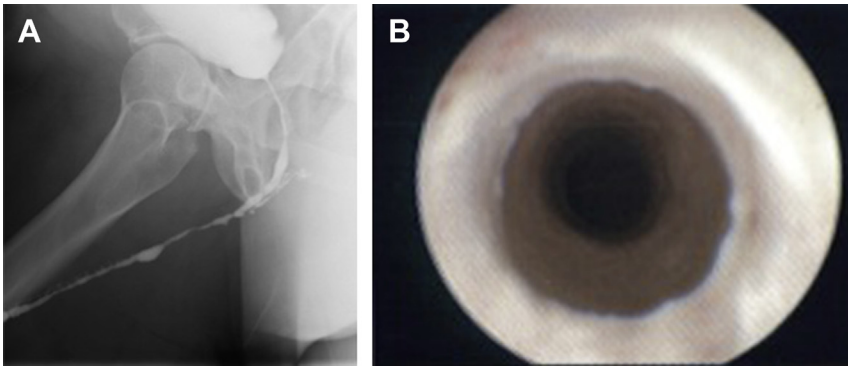
leukoplakia, and Zoon balanitis, may present with similar signs and symptoms. Therefore, the authors think a confirmatory biopsy is imperative to rule out malignant and premalignant penile lesions and further guide therapy.<sup>4</sup> Moreover, because the external manifestations of LS do not accurately predict the degree of urethral involvement, they recommend a LUTS evaluation in all patients.

In those patients with self-reported LUTS or with an elevated American Urological Association Symptom Index score, a retrograde urethrogram is the study of choice to evaluate for urethral involvement ([Fig. 4](#)). In addition, cystoscopy can be performed, usually revealing a narrowed urethral lumen with pale mucosa. The presence of atypical cystoscopic findings, such as significant desquamation, focal nodular narrowing, and ulcerated or bleeding mucosa, may signify malignant transformation and warrant a biopsy.

Urethral involvement of LS usually results from proximal progression of meatal LS. However, Liu and colleagues<sup>29</sup> reported in a cohort of 70 patients with isolated bulbar urethral stricture disease that almost 26% of men had histologic findings diagnostic of LS with no evidence of distal involvement. In this cohort, patients with LS on re-examination of the abnormality tended to have a previous failed intervention.<sup>29</sup> In a large observational study, Palminteri and colleagues<sup>30</sup> reported 1439 men undergoing urethroplasty. Of these patients, 193 (13.4%) were due to LS. Penile urethral strictures due to LS occurred in 107 patients, pan-urethral in 69 patients, and anterior urethral (penile and bulbar) in 17 patients. Interestingly, no isolated instances of LS and bulbar strictures were noted. Similarly, Barbagli and colleagues<sup>31</sup> reported 925 patients with a history of urethral



**Fig. 3.** (A) Glanular and (B) meatal involvement with LS.



**Fig. 4.** (A) Retrograde urethrogram in patient with LS and evidence of biopsy-proven panurethral stricture disease. (B) Cystoscopy of patient with LS demonstrating an irregular lumen with concentric white scar bands consistent with LS. Tissue is normally friable and minimally pliable.

stricture disease undergoing urethral reconstruction and found LS as the cause in 14% of the patients.

Although these studies do indicate that skip lesions and isolated urethral lesions are possible, the authors have not observed this in their practice. Regardless, these findings merit consideration when managing isolated bulbar urethral strictures because of the higher risk of recurrence in patients with LS.

### MANAGEMENT OF GENITAL LICHEN SCLEROSIS

The 3 overarching goals of management are alleviation of symptoms, prevention and treatment of urethral stricture disease, and prevention and detection of malignant transformation. In their practice, the authors have developed 3 additional goals to also address improving quality of life:

1. Unobstructed voiding
2. Painless intercourse
3. Adequate cosmesis<sup>32</sup>

As a result, the authors have shifted their paradigm in the management of LS. Most patients can be treated with minimally invasive therapies, including high-potency steroids and self-calibration before embarking on potentially morbid and invasive surgical interventions.<sup>33</sup>

Most patients afflicted by LS can be treated with conservative therapies before surgical intervention (Fig. 5). Classically, LS involving the foreskin, glans, and meatus can initially be managed by a short course of topical steroids. In the authors' practice, clobetasol propionate 0.05% topical application provides resolution of many of the bothersome presenting symptoms.

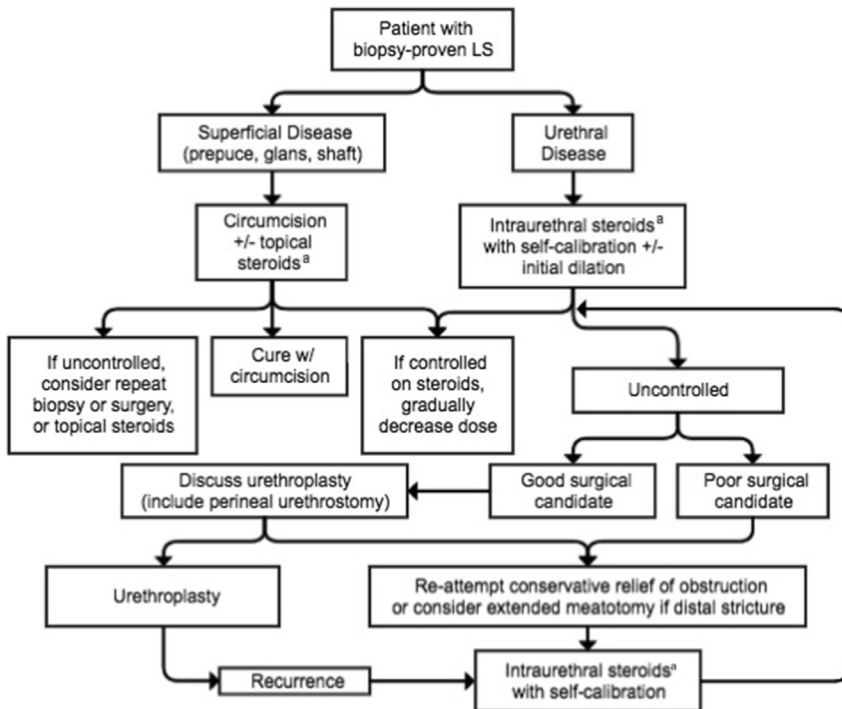
Kyriakou and colleagues<sup>34</sup> reported a 90.2% success rate in treatment with newly diagnosed,

biopsy-proven genital LS in a cohort of 41 men. There were statistically significant improvements in patient-reported outcomes and objective physician measures with the use of clobetasol propionate 0.05% cream for 8 weeks. Long-term sequelae of LS were not assessed, but the authors' treatment goals focus on symptom relief and prevention of disease progression. Tausch and Peterson<sup>35</sup> reported a subgroup of patients with LS involving only the penile foreskin and glans, who were treated with an aggressive combination of clobetasol ± circumcision. In this subgroup, no recurrences were noted on long-term follow-up (mean of 44.2 months).

Classically, urethral involvement of LS is managed surgically. However, Potts and colleagues<sup>33</sup> recently reported a cohort of men with biopsy-proven LS and urethral stricture disease managed with intraurethral steroids with excellent results. In this cohort, an intraurethral steroid regimen consisting of self-calibration twice daily for 3 months with a clobetasol-lubricated catheter resulted in a success rate of 89%. Furthermore, no patients in the series progressed to requiring formal surgical intervention. The promising results of this approach provide a significant minimally invasive option for urologists and patients alike before consideration of formal surgical intervention.

Surgical intervention is still needed when the disease process is extensive, bothersome, or recalcitrant to conservative therapy. In a series of 287 patients, Depasquale and colleagues<sup>18</sup> demonstrated that 92% of men with foreskin or glans involvement had a long-term cure with circumcision alone. In their practice, the authors have noted that circumcision alone may alleviate mild glans changes obviating further therapy.

Meatal stenosis and distal urethral strictures secondary to LS may be treated with topical



**Fig. 5.** Updated algorithm for management of biopsy-proven LS in men. <sup>a</sup> Steroid application BID for 2–3 months. BID, twice a day.

steroids, intermittent self-calibration, or surgical intervention, including urethral reconstruction with buccal grafts or extended meatotomy. When an extended meatotomy is performed, the penis will have a hypospadiac appearance. Excellent success with extended meatotomy has been reported for complex fossa navicularis and distal strictures. In a cohort of 16 patients with distal strictures who underwent extended meatotomy, success rates were as high as 87%.<sup>36</sup> The cause of these strictures was not described; however, Tausch and Peterson<sup>35</sup> reported outcomes of extended meatotomy in patients with known LS. Of the 12 patients treated, there were no recurrences identified.

Morey and colleagues<sup>36</sup> described the use of a first-stage Johanson technique to perform an extended meatotomy in patients with distal urethral strictures. In this technique, the meatus is open ventrally until healthy patent mucosa is noted and easily calibrated with a 24-Fr bougie à boule. The edges are marsupialized with absorbable suture (**Fig. 6**).

Distal urethroplasty in the management of urethral stricture disease resulting from LS is typically performed with a substitution urethroplasty technique rather than a fasciocutaneous flap approach due to the high failure rate of the latter. Venn and Mundy<sup>37</sup> reported outcomes of 12 patients with

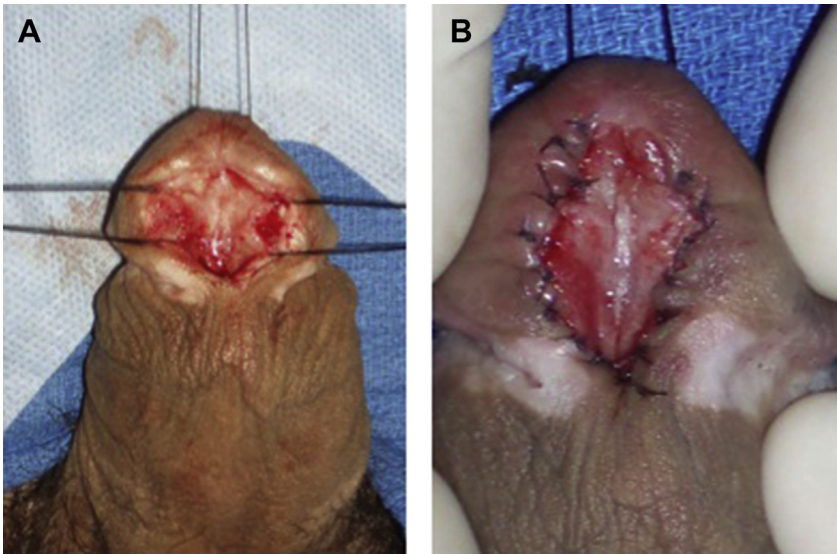
LS who underwent a local pedicle flap distal urethroplasty. They report 100% failure in these patients and advocate against the use of fasciocutaneous flaps for this disease process. Meeks and colleagues<sup>38</sup> noted a significant difference in recurrence distal strictures between men with LS and those without LS (recurrence in LS 20.5%; no LS 7.5%;  $P < .05$ ).

Treatment of pendulous stricture disease is driven by the quality of existent tissue and prior interventions. A one-stage repair with nongenital tissue, such as buccal mucosa, is feasible. However, various reports demonstrate a high failure rate with this approach.<sup>35,39,40</sup>

## TWO-STAGE REPAIR

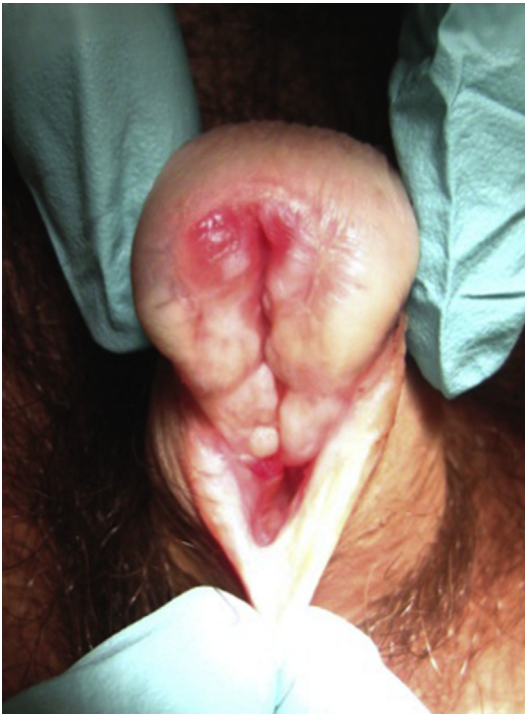Extensive cases of urethral stricture disease due to LS with an inadequate native urethral plate for primary one-stage repair represent a reconstructive challenge. In these cases, a staged surgical approach often yields better outcomes than single-stage reconstruction.<sup>41</sup>

The first stage of this approach, as described by Barbagli, through a midline penile incision, involves complete excision of all affected urethra and full opening of the glans. Buccal mucosa is harvested and grafted to the tunica albuginea allowing for maturation over a 6- to 12-month



**Fig. 6.** (A) Meatotomy with exposed urethral plate and (B) Meatoplasty in patients with severe distal urethral stricture secondary to LS.

period. After the maturation process is complete, the graft is evaluated for appropriate take and recurrent LS. If the graft take is not acceptable or LS has recurred, then repeating the first stage may be required (Fig. 7). However, if the graft take is acceptable and free of recurrence, then



**Fig. 7.** Recurrence of LS after urethroplasty with buccal graft.

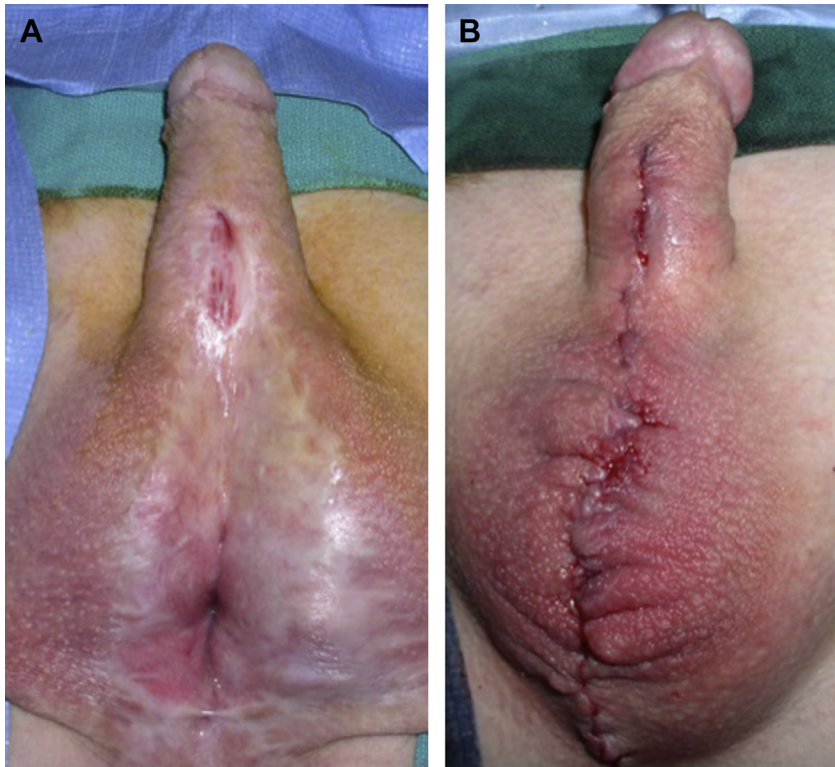one can proceed to the second stage. In these repairs, the use of fasciocutaneous flaps with genital skin is avoided secondary to disease recurrence in the genital skin.<sup>37</sup>

During the second stage, an approximately 28-mm-wide urethral plate is needed. This plate is incised and tubularized. Fistula formation is a known complication in patients with urethral stricture disease secondary to LS undergoing urethral reconstruction, with an incidence of approximately 1.9%.<sup>39,42</sup> To reduce fistula formation, closure with multiple layers in a nonoverlapping suture line technique and placement of a dartos or tunica vaginalis flap is recommended. The penile skin is then closed in the midline (Fig. 8).<sup>41</sup>

#### RECURRENCE AFTER 2-STAGE REPAIRS

The success rates for 2-stage repairs are traditionally lower when compared with uncomplicated urethral reconstruction, due to a variety of factors, including the extensive nature of preoperative urethral stricture disease and the recurrent nature of LS. Kulkarni and colleagues<sup>43</sup> demonstrated a recurrence rate of 27% at a mean follow-up time of 43 months for 2-stage buccal urethral reconstruction.

Peterson and colleagues<sup>44</sup> reported a series of 63 patients with LS, 19 who underwent first-stage repair. In this cohort, 11 patients ultimately underwent the second-stage reconstruction. They reported a recurrence rate of stricture in 2/11 (18%). Patel and colleagues<sup>40</sup> recently reported their observations in the management of stricture disease in patients with LS. Their cohort included



**Fig. 8.** (A) Healed first-stage urethroplasty. (B) Completed second-stage repair.

37 patients undergoing a 2-staged repair. Recurrence of LS was noted to occur on the first stage in 24% of the patients. Of the patients who underwent the second stage of their repair, recurrence was noted in 21% of those patients. These reports highlight the difficult challenge that LS poses on urethral reconstruction.

### PERINEAL URETHROSTOMY

Perineal urethrostomy (PU) is a recognized alternative for proximal diversion in the nonsalvageable urethra. PU as the final point in management of an obstructed lower urinary tract is becoming more acceptable in men with LS and is an attractive option for patients with extensive urethral LS who may be unwilling or medically unfit to proceed with a 2-stage repair. Prior reports suggest patient satisfaction with a PU is acceptable.<sup>41,44</sup> Barbagli and colleagues<sup>45</sup> recently reported their experience in men undergoing PU demonstrating a 97% patient satisfaction rate.

The 2 main techniques, the Blandy PU and the “7-flap,” use a wide-based perineal skin flap to avoid restenosis. In both cases, restenosis of the PU is minimized by the utilization of a flap instead of a puncture. The Blandy PU uses a posteriorly based skin flap raised through a U-shaped

perineal incision.<sup>44</sup> The proximal bulbar urethra is secured to the flap of perineal tissue with interrupted, absorbable sutures and matured at the skin level. Urinary continence is maintained because dissection is distal to the external urethral sphincter. The “7-flap,” as described by French and colleagues,<sup>46</sup> uses a laterally based perineal skin flap. This flap is secured to the lateral aspect of the calibrated proximal bulbar urethral stump and matured at the skin level.

### RECURRENCE WITH PERINEAL URETHROSTOMY

There is a wide range of reported recurrence for PU (72%–100%).<sup>43,44</sup> In his series of 173 patients, Barbagli reports a 70% success rate. Even though some patients needed up to 5 additional procedures, nearly all (97%) were satisfied with PU and would choose it again.<sup>45</sup> Peterson and colleagues<sup>44</sup> found that almost half of planned 2-stage repairs (8/19, 42%) elected to not proceed to the second stage, rendering them with a functional PU without significantly affecting quality of life.

Morey and colleagues<sup>46</sup> report a 90% success rate when using the “7-flap technique.” Among those who failed, only endoscopic dilation was



required, with no further open surgical revision needed. Patel and colleagues<sup>40</sup> also reported PU outcomes as a primary procedure of extensive urethral stricture disease. They noted a 93% success rate at a mean follow-up time of 14 months.

## SUMMARY

LS is a progressive disease with a varied presentation and can be a challenging problem to manage. Localized disease to the foreskin and glans can be treated with potent topical steroids or circumcision. Urethral involvement occurs in 20% of patients. The extent of urethral involvement ranges from meatal only to panurethral. Intraurethral steroids with self-calibration may provide symptomatic relief to a large proportion of patients. Urethroplasty in this population has a higher risk of recurrence or need for multistage repairs to achieve a patent urethra. Last, in a highly selected group of patients, a PU may be advisable.

## REFERENCES

1. New nomenclature for vulvar disease. *Obstet Gynecol* 1976;47(1):122–4.
2. Powell JJ, Wojnarowska F. Lichen sclerosis. *Lancet* 1999;353(9166):1777–83.
3. Das S, Tunuguntla HS. Balanitis xerotica obliterans—a review. *World J Urol* 2000;18(6):382–7.
4. Pugliese JM, Morey AF, Peterson AC. Lichen sclerosis: review of the literature and current recommendations for management. *J Urol* 2007;178(6):2268–76.
5. Riddell L, Edwards A, Sherrard J. Clinical features of lichen sclerosis in men attending a department of genitourinary medicine. *Sex Transm Infect* 2000;76(4):311–3.
6. Azurdia RM, Luzzi GA, Byren I, et al. Lichen sclerosis in adult men: a study of HLA associations and susceptibility to autoimmune disease. *Br J Dermatol* 1999;140(1):79–83.
7. Laymon CW. Lichen sclerosis et atrophicus and related disorders. *AMA Arch Derm Syphilol* 1951;64(5):620–7.
8. Regauer S. Immune dysregulation in lichen sclerosis. *Eur J Cell Biol* 2005;84(2–3):273–7.
9. Oyama N, Chan I, Neill SM, et al. Autoantibodies to extracellular matrix protein 1 in lichen sclerosis. *Lancet* 2003;362(9378):118–23.
10. Bjekic M, Sipetic S, Marinkovic J. Risk factors for genital lichen sclerosis in men. *Br J Dermatol* 2011;164(2):325–9.
11. Cantwell AR Jr. Histologic observations of pleomorphic, variably acid-fast bacteria in scleroderma, morphea, and lichen sclerosis et atrophicus. *Int J Dermatol* 1984;23(1):45–52.
12. Eisendle K, Grabner T, Kutzner H, et al. Possible role of *Borrelia burgdorferi* sensu lato infection in lichen sclerosis. *Arch Dermatol* 2008;144(5):591–8.
13. Farrell AM, Millard PR, Schomberg KH, et al. An infective aetiology for vulvar lichen sclerosis re-addressed. *Clin Exp Dermatol* 1999;24(6):479–83.
14. Edmonds E, Mavin S, Francis N, et al. *Borrelia burgdorferi* is not associated with genital lichen sclerosis in men. *Br J Dermatol* 2009;160(2):459–60.
15. Pock L. Koebner phenomenon in lichen sclerosis et atrophicus. *Dermatologica* 1990;181(1):76–7.
16. Milligan A, Graham-Brown RA, Burns DA. Lichen sclerosis et atrophicus following sunburn. *Clin Exp Dermatol* 1988;13(1):36–7.
17. Yates VM, King CM, Dave VK. Lichen sclerosis et atrophicus following radiation therapy. *Arch Dermatol* 1985;121(8):1044–7.
18. Depasquale I, Park AJ, Bracka A. The treatment of balanitis xerotica obliterans. *BJU Int* 2000;86(4):459–65.
19. Barbagli G, Palminteri E, Mirri F, et al. Penile carcinoma in patients with genital lichen sclerosis: a multicenter survey. *J Urol* 2006;175(4):1359–63.
20. Powell J, Robson A, Cranston D, et al. High incidence of lichen sclerosis in patients with squamous cell carcinoma of the penis. *Br J Dermatol* 2001;145(1):85–9.
21. Velazquez EF, Cubilla AL. Lichen sclerosis in 68 patients with squamous cell carcinoma of the penis: frequent atypias and correlation with special carcinoma variants suggests a precancerous role. *Am J Surg Pathol* 2003;27(11):1448–53.
22. Zaid UB, Lavien G, Potts B, et al. Malignancy in biopsy proven penile lichen sclerosis [abstract]. Munich (Germany): European Urology Association; 2016.
23. Meuli M, Briner J, Hanimann B, et al. Lichen sclerosis et atrophicus causing phimosis in boys: a prospective study with 5-year followup after complete circumcision. *J Urol* 1994;152(3):987–9.
24. Kiss A, Kiraly L, Kutasy B, et al. High incidence of balanitis xerotica obliterans in boys with phimosis: prospective 10-year study. *Pediatr Dermatol* 2005;22(4):305–8.
25. Yardley IE, Cosgrove C, Lambert AW. Paediatric preputial pathology: are we circumcising enough? *Ann R Coll Surg Engl* 2007;89(1):62–5.
26. Wallace HJ. Lichen sclerosis et atrophicus. *Trans St Johns Hosp Dermatol Soc* 1971;57(1):9–30.
27. Kizer WS, Prarie T, Morey AF. Balanitis xerotica obliterans: epidemiologic distribution in an equal access health care system. *South Med J* 2003;96(1):9–11.
28. Nelson DM, Peterson AC. Lichen sclerosis: epidemiological distribution in an equal access health care system. *J Urol* 2011;185(2):522–5.
29. Liu JS, Walker K, Stein D, et al. Lichen sclerosis and isolated bulbar urethral stricture disease. *J Urol* 2014;192(3):775–9.

30. Palminteri E, Berdondini E, Verze P, et al. Contemporary urethral stricture characteristics in the developed world. *Urology* 2013;81(1):191–6.
31. Barbagli G, Palminteri E, Balo S, et al. Lichen sclerosus of the male genitalia and urethral stricture diseases. *Urol Int* 2004;73(1):1–5.
32. Belsante MJ, Selph JP, Peterson AC. The contemporary management of urethral strictures in men resulting from lichen sclerosus. *Transl Androl Urol* 2015;4(1):22–8.
33. Potts BA, Belsante MJ, Peterson AC. Intraurethral steroids are a safe and effective treatment for stricture disease in patients with biopsy-proven lichen sclerosus. *J Urol* 2016;195(6):1790–6.
34. Kyriakou A, Patsialas C, Patsatsi A, et al. Treatment of male genital lichen sclerosus with clobetasol propionate and maintenance with either methylprednisolone aceponate or tacrolimus: a retrospective study. *J Dermatolog Treat* 2013;24(6):431–4.
35. Tausch TJ, Peterson AC. Early aggressive treatment of lichen sclerosus may prevent disease progression. *J Urol* 2012;187(6):2101–5.
36. Morey AF, Lin HC, DeRosa CA, et al. Fossa navicularis reconstruction: impact of stricture length on outcomes and assessment of extended meatotomy (first stage Johanson) maneuver. *J Urol* 2007;177(1):184–7 [discussion: 187].
37. Venn SN, Mundy AR. Urethroplasty for balanitis xerotica obliterans. *Br J Urol* 1998;81(5):735–7.
38. Meeks JJ, Barbagli G, Mehdiratta N, et al. Distal urethroplasty for isolated fossa navicularis and meatal strictures. *BJU Int* 2012;109(4):616–9.
39. Levine LA, Strom KH, Lux MM. Buccal mucosa graft urethroplasty for anterior urethral stricture repair: evaluation of the impact of stricture location and lichen sclerosus on surgical outcome. *J Urol* 2007;178(5):2011–5.
40. Patel CK, Buckley JC, Zinman LN, et al. Outcomes for management of lichen sclerosus urethral strictures by 3 different techniques. *Urology* 2016;91:215–21.
41. Barbagli G. When and how to use buccal mucosa grafts in penile and bulbar urethroplasty. *Minerva Urol Nefrol* 2004;56(2):189–203.
42. Acimovic M, Milojevic B, Milosavljevic M, et al. Primary dorsal buccal mucosa graft urethroplasty for anterior urethral strictures in patients with lichen sclerosus. *Int Urol Nephrol* 2016;48(4):541–5.
43. Kulkarni S, Barbagli G, Kirpekar D, et al. Lichen sclerosus of the male genitalia and urethra: surgical options and results in a multicenter international experience with 215 patients. *Eur Urol* 2009;55(4):945–54.
44. Peterson AC, Palminteri E, Lazzeri M, et al. Heroic measures may not always be justified in extensive urethral stricture due to lichen sclerosus (balanitis xerotica obliterans). *Urology* 2004;64(3):565–8.
45. Barbagli G, De Angelis M, Romano G, et al. Clinical outcome and quality of life assessment in patients treated with perineal urethrostomy for anterior urethral stricture disease. *J Urol* 2009;182(2):548–57.
46. French D, Hudak SJ, Morey AF. The “7-flap” perineal urethrostomy. *Urology* 2011;77(6):1487–9.